




Original Article

Corresponding Author

Fujio Ito

 <https://orcid.org/0000-0001-5231-7657>

Spine Surgery Department, Aichi Spine Hospital, 31-1, Kamiike, Goroumaru Inuyama-shi, Aichi-ken, Japan

Tel: +81-568209100

Fax: +81-568209107

E-mail: ito@itoortho.or.jp

Received: December 29, 2018

Revised: February 5, 2019

Accepted: February 7, 2019

Step-by-Step Sublaminar Approach With a Newly-Designed Spinal Endoscope for Unilateral-Approach Bilateral Decompression in Spinal Stenosis

Fujio Ito¹, Zenya Ito¹, Motohide Shibayama¹, Shu Nakamura¹, Minoru Yamada¹, Hideki Yoshimatu¹, Mikinobu Takeuchi¹, Kenzo Shimizu¹, Yasushi Miura²

¹Spine Surgery Department, Aichi Spine Hospital, Aichi-ken, Japan

²Tokyo Spine Clinic, Tokyo, Japan

Objective: Spinal stenosis is increasingly common due to population aging. In elderly patients with lumbar central canal stenosis (LCCS), minimizing muscle damage and bone resection is particularly important. We performed a step-by-step operation with a newly designed spinal endoscope to obtain adequate decompression in patients with spinal stenosis.

Methods: From April 2015 to August 2016, 78 patients (48 males, 30 females) with LCCS (91 segments) underwent endoscopic decompression using a newly designed endoscope system. The inclusion criteria were: (1) neurogenic intermittent claudication with or without radiculopathy, (2) LCCS, and (3) having exhausted conservative treatment (>3 months). The exclusion criteria were: (1) >10° of instability, (2) spondylolisthesis grade II or greater according to the Meyerding criteria, (3) foraminal stenosis, (4) vascular intermittent claudication, (5) infection, and (6) stenosis combined with malignancy. We performed a step-by-step procedure using a newly designed endoscope system for unilateral-approach bilateral decompression. We used the same incision for 2–3 segments, only moving the skin.

Results: The mean follow-up was 2.3 ± 1.3 years. *Excellent* or *good* results were found according to the MacNab criteria in 85.9% of cases (67 of 78). The visual analogue scale, Japanese Orthopedic Association score, and Oswestry Disability Index showed significant decreases at 1 month, persisting until the 2-year follow-up. Dural tear occurred in 4 cases (5.1%), and patch repair was performed under endoscopy. No patients experienced aggravated instability requiring surgery.

Conclusion: We obtained *good* results with endoscopic decompression surgery using a newly designed instrument that minimized muscle and bone damage in elderly patients with spinal stenosis.

Keywords: Unilateral approach bilateral decompression, Spinal endoscopy, Step-by-step procedure, Minimally invasive laminotomy



This is an Open Access article distributed under the terms of the Creative Commons Attribution Non-Commercial License (<http://creativecommons.org/licenses/by-nc/4.0/>) which permits unrestricted non-commercial use, distribution, and reproduction in any medium, provided the original work is properly cited.

Copyright © 2019 by the Korean Spinal Neurosurgery Society

INTRODUCTION

Lumbar central canal stenosis (LCCS) is a degenerative disease, which is a critical cause of low back pain, gait disturbance,

daily living activity dysfunction, locomotive syndrome in the aging society, and eventually bedridden. Most LCCS patients receive conservative treatment such as drug therapy and block injection to alleviate their symptoms. Surgery is recommended

in case of conservative treatment failure or progressive or severe neurological deficit.

Because the open decompression technique may cause many complications over the age of 75, risk will also increase with longer hospitalization and greater invasion.¹ From the anatomical point of view, the width of the inferior articular process becomes narrower particularly at the high-level lumbar segments. In wide laminectomy or open fenestration, some reports have suggested a relationship between poor clinical outcomes and large incisions, muscle damage, inferior articular process fractures, postoperative instability, and the like.

To solve this problem, microendoscopy and microscopy methods using a 16-mm tubular retractor as minimally invasive surgery have been introduced. Among these, to discuss 2 important surgical methods,²⁻⁵ (1) with the unilateral approach and bilateral decompression approaches, it is necessary to remove the spinous process base to a large extent in order to avoid excessive resection or fracture of a narrow inferior articular process and bring the retractor closer to the contralateral side. (2) In another spinous process splitting approach, the inferior articular process and paraspinal muscles are preserved, but part of the posterior elements (spinous process and interspinous ligaments) must be broken.

Excessive muscle and bone resection may also cause postoperative hematoma, so it is important to keep the resection range as minimal as possible.⁶

On the other hand, to prevent postoperative spinal instability, it is not uncommon to choose fusion surgery. However, fusion surgery is not only highly invasive for elderly people, but there is also a risk that degeneration (adjacent-segment disease) may develop at mobile segments above or below an intervertebral fusion.

From the above, it is important for elderly LCCS to restrict muscle injury/bone resection to a small extent and also perform reliable decompression. For that purpose, percutaneous endoscopic surgery using a narrow outer tube with a large working space in the unilateral approach bilateral decompression approach method seems to be appropriate.

The endoscopic decompression for spinal stenosis used this time is performed under continuous water irrigation. In general, with the uniportal bilateral approach method it is easy to insert the tip of the outer tube toward the contralateral oblique position, and it is easy to decompress the hypertrophied bone and the ligamentum flavum. However, the inclination of the tip of the outer tube to the ipsilateral side is difficult, the thicker the outer tube, the more bone removal on the ipsilateral side

will increase and fractures of the articular process can occur. The tip of the thin outer tube used this time is comparatively easy to incline to the ipsilateral side, so ipsilateral bone (facet joint) resection can be done in a small range. Here, we describe our use of endoscopic decompression in the treatment of LCCS and document our clinical outcomes in patients with this condition.

MATERIALS AND METHODS

1. Materials

Seventy-eight patients (48 males, 30 females) of LCCS, 91 segments were treated and investigated between April 2015 and August 2016 by endoscopic decompression using newly designed spinal endoscope.

Inclusion criteria were as follows: (1) neurogenic intermittent claudication with or without radiculopathy, (2) LCCS, and (3) exhausted conservative treatments more than 3 months. Exclusion criteria were (1) instability with more than 10° of posterior opening spinal segment instability in dynamic radiographs, (2) spondylolisthesis grade II or greater in Meyerding criteria, (3) foraminal stenosis, (4) patients who have vascular intermittent claudication, (5) infection, and (6) stenosis combined with malignancy.

Level determination of canal stenosis depended on findings of magnetic resonance imaging. Plain radiography of the lumbar spine, which was performed in flexion and extension positions in the lateral view, checked spinal instability. Computed tomography (CT) examined the presence or absence of lateral recess stenosis, foraminal stenosis or calcification of the ligamentum flavum.

Institutional Review Board consent (authorization number: 2018-3) was obtained for this study. We discussed methods of operation, the advantages and problems of surgery, time of operation, method of anesthesia, risk, postoperative course, etc. with the patients, and then we received informed consent from all patients.

2. Newly Designed Spinal Endoscope for Decompression of Spinal Stenosis

We used newly designed endoscope system (Maxmore Co., Ltd., Unterfoehring, Germany) that has larger inner working channel. Outer diameter of the cannula is 9.0 mm and that of the inner working channel is 5.3 mm compared with a percutaneous full endoscopy 4.1 mm (Richard Wolf GmbH, Knittlingen, Germany). In the larger inner working channel, we can use

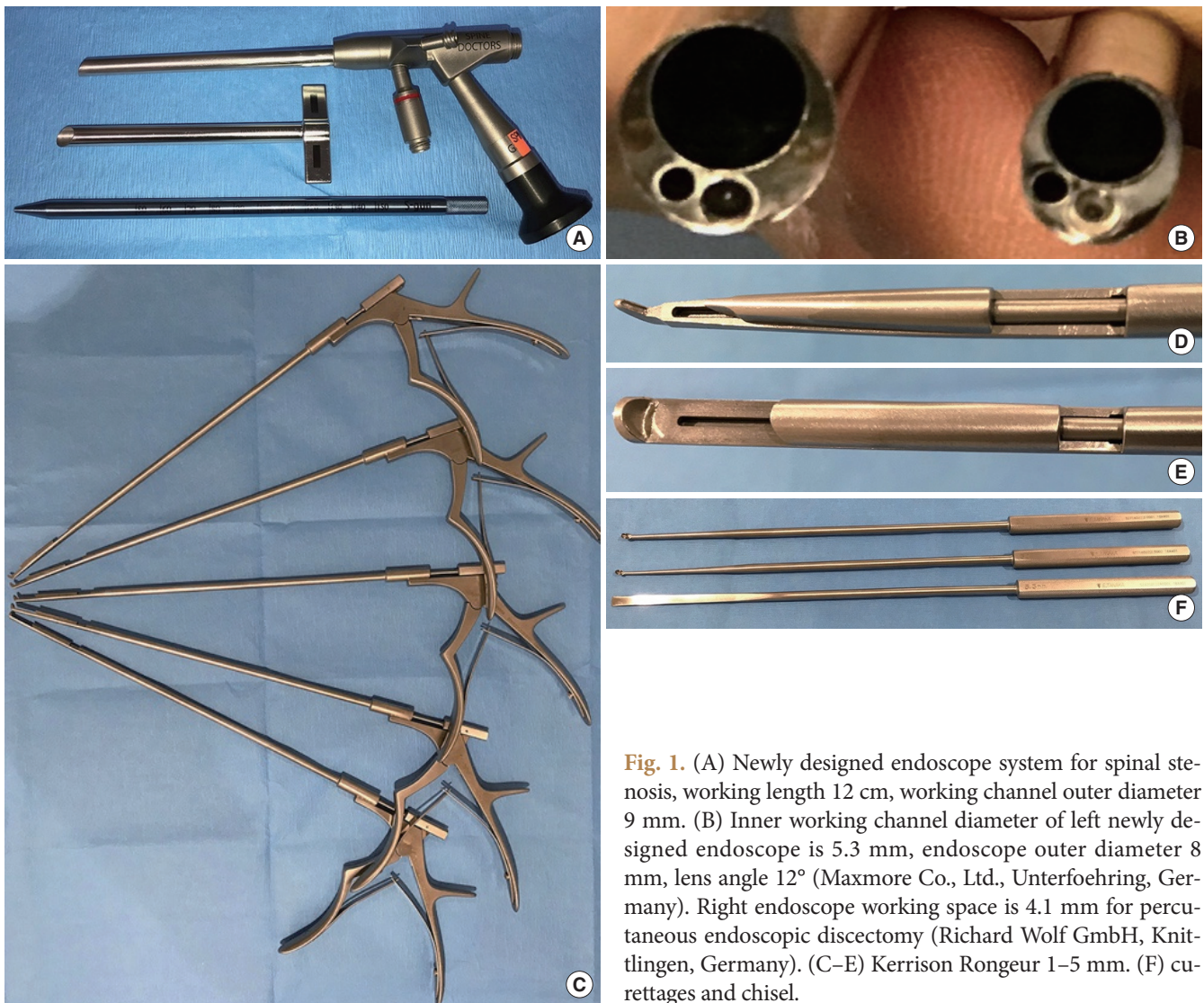


Fig. 1. (A) Newly designed endoscope system for spinal stenosis, working length 12 cm, working channel outer diameter 9 mm. (B) Inner working channel diameter of left newly designed endoscope is 5.3 mm, endoscope outer diameter 8 mm, lens angle 12° (Maxmore Co., Ltd., Unterfoehring, Germany). Right endoscope working space is 4.1 mm for percutaneous endoscopic discectomy (Richard Wolf GmbH, Knittlingen, Germany). (C–E) Kerrison Rongeur 1–5 mm. (F) curettages and chisel.

several sizes of endoscopic Kerrison punch and diamond burr. Newly designed endoscope has a 9.0-mm oblique outer tube, an 8.0-mm outer diameter, a 5.3-mm working channel, a 12-cm working cannula length, 19-cm total length of the endoscope, and 12° endoscope lens angle (Fig. 1A, B). Those characters are more suitable for spinal endoscopic surgery for spinal stenosis because the outer diameter smaller and the inner working channel is larger than the previous spinal endoscope. This character enabled us to use various sizes of rongeurs in the spinal endoscopic procedures. The diameter of the insertable endoscopic Kerrison rongeur is 5.0 mm in our newly designed spinal endoscope. Sizes range of these rongeurs bite parts are between 1 mm to 5 mm at each diameter, which are convenient for removing the ligamentum flavum and its entheses (Fig. 1C–E). We used from 3 to 5 mm diamond burrs (Stryker Co., Ltd., Ka-

lamazoo, MI, USA), and a diamond drill for Percutaneous Endoscopic Lumbar Discectomy (NSK-Nakanishi International, Co., Ltd., Osaka, Japan) can also be used during the endoscopic decompression procedure. In addition, there are also 3.5-mm forceps, a probe, a 3-mm curette, a punch and so on (Fig. 1F). A 3-mm bent probe is used for detachment of the ligamentum flavum from the lamina bone and to retract the root or dura (Fig. 1E). A radiofrequency electrode (Elliquance, Baldwin, NY, USA) is used for hemostasis and ablation of soft tissue.^{7,8}

3. Surgical Position · Incision

Under general endotracheal anesthesia the patients were in a prone position with mild flexion of the hip/knee. The disc level and interlaminar space were identified by image intensifier. The operator stood on the other side against bone hypertrophy, be-

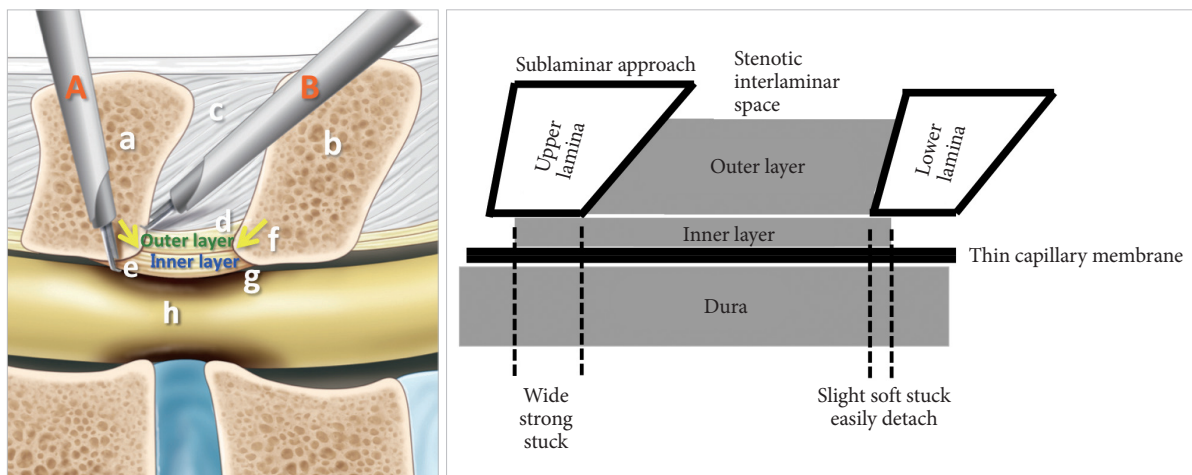


Fig. 2. Left panel: anatomical structure of the ligamentum flavum, right panel: schematic diagram of the ligamentum flavum. a, upper lamina; b, lower lamina; c, interspinous ligament; d, outer layer of ligamentum flavum; e, wide strongly stuck cephalad part of inner layer of ligamentum flavum; f, slight soft stuck caudad part of inner layer of ligamentum flavum; g, thin capillary membrane; h, dura; A, translaminar approach; B, sublaminar approach. Yellow arrow indicates borderline of inner and outer layer of ligamentum flavum.

cause it was easier to remove the superior articular process obliquely. A skin incision of approximately 9 mm in length was made targeting the boundary of the upper lamina and interlaminar space. One 8.0-mm dilator was inserted through the incision. In 2 segments, we moved only the skin using the same incision. For 3 segments, the incision was extended to about 1.2 cm, and the outer tube is pulled out subcutaneously and moved underneath.⁹

4. Patho-anatomical Consideration of Ligamentum Flavum in Spinal Stenosis

In the spinal stenosis, the interlaminar space is generally narrowed due to thickening of the laminae. In this situation, ligamentum flavum is thickened and ligamentum flavum is strongly and widely stuck underneath the upper laminae on the cephalad side (Fig. 2). Although the outer layer of ligamentum flavum is thick, it is easy to remove, but the inner layer of ligamentum flavum firmly attached to the inner surface of the bone especially in the cephalad portion (Fig. 2E, F). So lower part of upper lamina should be removed till to expose the epidural space sufficiently, to detach lots of the ligamentum flavum. First, the sublaminar approach is better to be selected, because the interlaminar space is narrow due to degeneration (Fig. 2B). On the other hand, caudad part of ligament is not so stuck to the lamina in spite of inner or outer layer, so it is easily detached. However, in order to prevent bleeding, should never cut the thin membrane containing the capillary just under the inner layer of

ligamentum flavum. In some cases of severe stenosis, the ligamentum flavum and the dura mater adhere to each other severely due to severe spinal canal compression. Because of that, firstly, outer layer of ligamentum flavum should be detect and resect sequentially to minimize nerve damage.

Especially, for the beginners, the deep layer must be preserved till the end of procedure to avoid dural tear and excessive bleeding.^{10,11}

5. Step-by-Step Sublaminar Approach: Assume L4–5 Stenosis (Supplementary video clip 1)

1) Step 1: docking step (docking of the working channel under the sublaminar area)

The surgeon stands on the side with less bone hypertrophy. In the example of central canal stenosis at L4/5, under the anterior-posterior view of the fluoroscopy, the medial end of the lamina is a target for insertion, which is palpable as a dimple between the tip of spinous process and erector spinae muscle. Under the lateral view of the fluoroscopy, mark with a pen as an incision line of 9.0 mm from the lower edge of the superior lamina (L4) to the caudal side. After performing a skin incision of 9.0 mm, insert the dilator rod of 8.0 mm onto the interlaminar space. Insert the outer tube with oblique mouth in layers over it. After pulling the dilator rod, insert the 8.0-mm endoscope and insert the oblique oval mouth of the outer tube little by little until the surface of the yellow ligament is visible on the monitor. Firstly, as quickly as possible, ablate the soft tissue and

reach the surface of the ligamentum flavum. Next, coagulate the soft tissues of the superior lamina and the interlaminar space using a bipolar-electrodes, remove an outer layer of the ligamentum flavum with forceps. When you clarify the contour around the lamina bone early, the orientation is easy to be attached. The deep layer must be preserved till the last procedure (Fig. 3).

2) Step 2: passing and cephalad liberation step (passing to the contralateral side and liberation of cephalad portion of ligamentum flavum through the sublaminar path)

First of all, L4 lamina lower edge must be adequately resected to the head side using a 4-mm steel drill until the ligamentum

flavum liberate (sublaminar approach). Then, the base of the spinous process is shaved, the outer tube is allowed to be inserted toward the contralateral side. Next, a separation maneuver is performed using a curved probe so that the deep entheses of the ligamentum flavum was detached from the lamina surface. Then a 2-mm Kerrison punch resects the entheses of the deep ligament layer from the lamina inner wall and liberates the ligamentum flavum (Fig. 4).

3) Step 3: caudad liberation step (liberation of caudad portion of ligamentum flavum)

Next, we detach the ligamentum flavum from the upper mar-

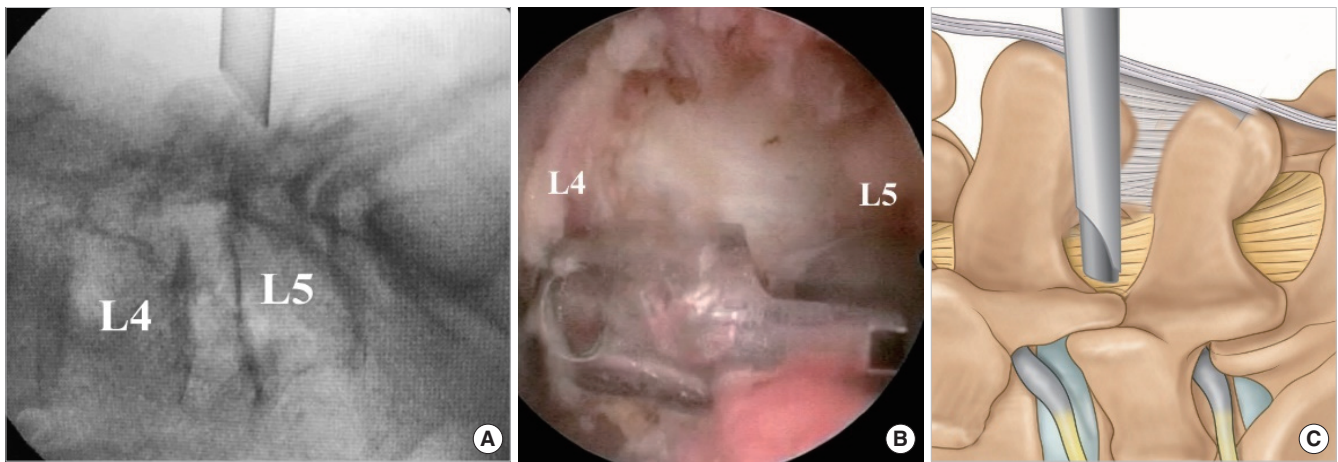


Fig. 3. Step 1. Docking step of the working channel. (A) under the fluoroscopic guidance, working channel insert on the deepest point of outer layer of ligamentum flavum. (B) After clearing the soft tissue using the radiofrequency coagulation, structure around the outer layer of ligamentum flavum exposed. (C) Illustrative description of docking step of the working channel.

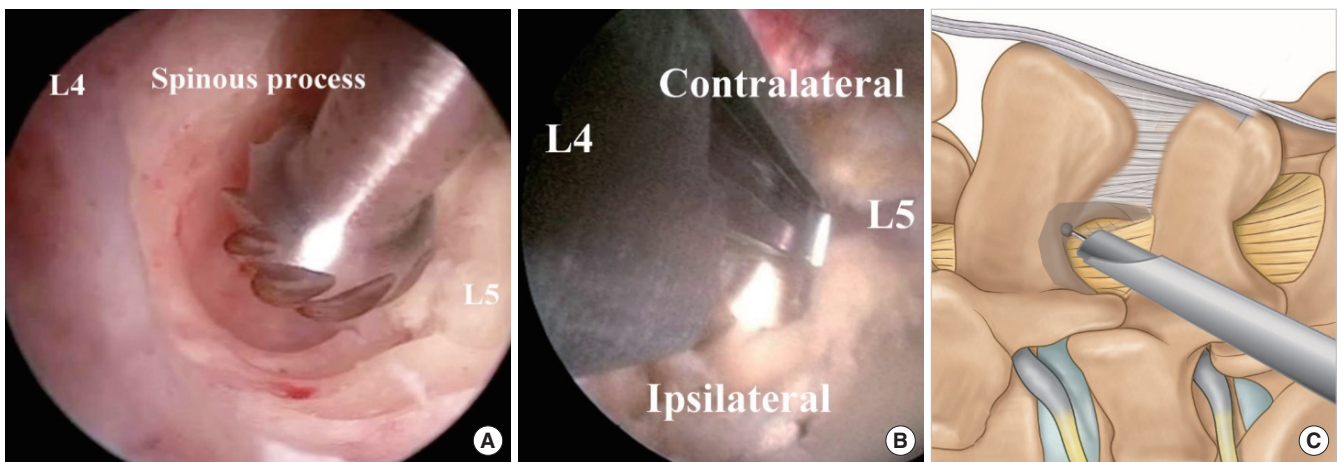


Fig. 4. Step 2. Passing and cephalad liberation step. (A) Yellow ligament strongly and widely stuck underneath the L4 lamina. To liberate the cephalad part of inner layer of ligamentum flavum, shaving L4 lamina and spinous process base sufficiently needed. (B) After sufficiently shaving, cephalad portion of inner layer of ligamentum flavum can liberate from stuck upper lamina. (C) Illustrative description of passing and liberation step.

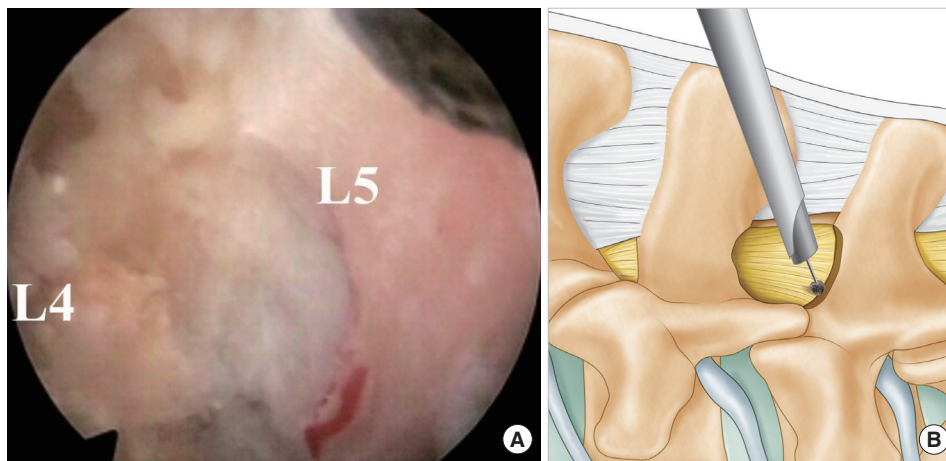


Fig. 5. Step 3. Caudad liberation step. (A) Intraoperative images of caudad liberation step. (B) Illustrative images of caudad liberation step.

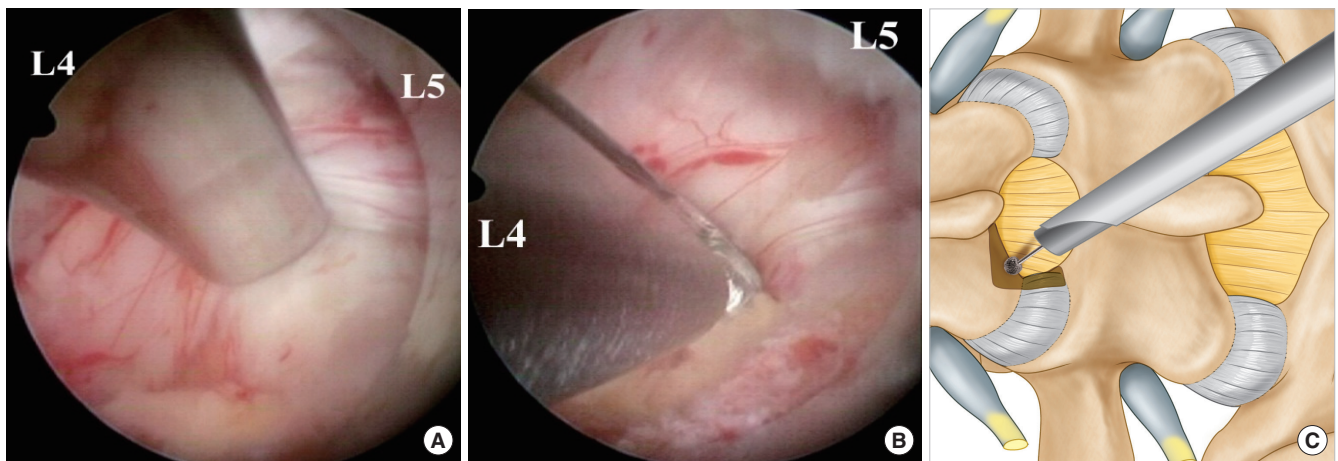


Fig. 6. Step 4. Trumpet shape Ipsilateral decompression step. (A, B) intraoperative images of trumpet shape ipsilateral decompression step. (C) Illustrative images of trumpet shape ipsilateral decompression step.

gin of the L5 lamina during laminotomy. In this area, the ligamentum flavum is not sticking strongly to the inner wall of the lamina, and when the drill is operated almost vertically, both the superficial and deep layers of the ligamentum flavum are relatively easily removed from the lamina wall. However, in order to prevent bleeding, never cut the thin membrane containing the capillary beneath the ligamentum flavum (Fig. 5).

4) Step 4: trumpet shape ipsilateral decompression step (ipsilateral decompression as a trumpet shape)

In the case of a narrow interlaminar space, the inner wall of the ipsilateral lamina is shaved with a drill near the attachment of the ligamentum flavum. A curved probe dissects the entheses of the ligamentum flavum from the lamina. Shave the lamina to be a straight line from cephalad to the caudad. It is necessary to

retract the nerve root using a dissector gently and create a space for a Kerrison punch. It is important that the L5 superior articular facet has to be removed in the shape of a trumpet bell in order to decompress the ipsilateral lateral recess stenosis. Care should be taken not to damage the dura or nerve root (Fig. 6).

5) Step 5: whole decompression step (bilateral decompression step after contralateral decompression)

The border of the contralateral ligamentum flavum is difficult to discern under the lamina wall. After the contralateral shallow layer is detached in a longitudinal direction from the lamina wall with drilling, the entheses of the deep ligament is detached using a probe. The deep ligament insertion is cut off from the contralateral detached, the deep layer is split along the midline using a ball probe and the flavum itself begins to float.

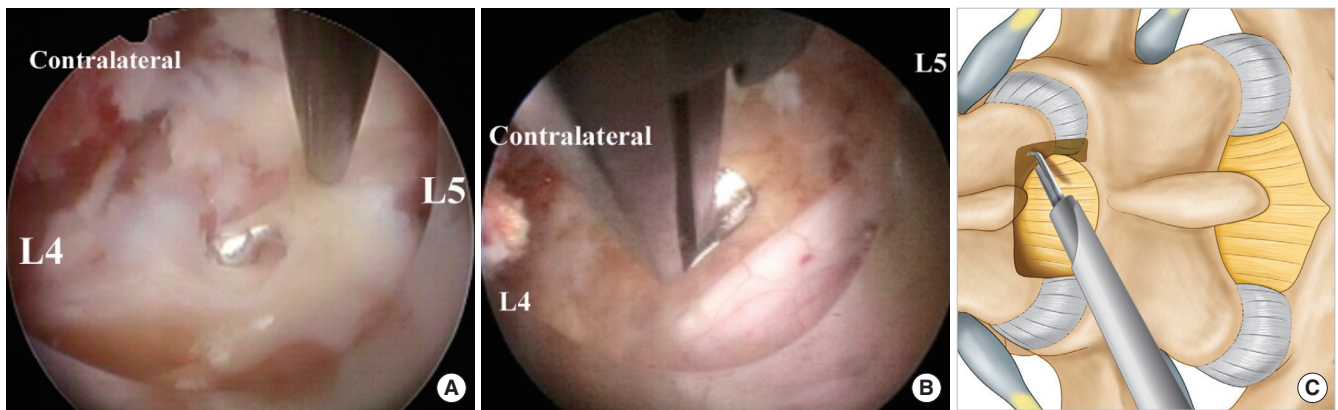


Fig. 7. Step 5. Whole decompression step. (A, B) Intraoperative images of whole decompression step. (C) Illustrative images of whole decompression step.

A small angled curette, or flexible bipolar can be used to gently dissect the ligament in the longitudinal direction and to identify the capillary and fat tissue between the ligamentum flavum and the underlying dura. After carefully peeling the fibrous adhesions with the dura, remove the bilateral ligaments with a Kerrison punch, and dural pulsation is observed. After identifying the spinal nerve roots, foraminotomy is performed bilaterally. Importantly, the right L5 superior articular facet also has to be removed in the shape of a trumpet bell (Fig. 7).

RESULTS

A total of 91 levels on 78 patients with LCCS were operated using the step-by-step sublaminar endoscopic decompression method, and the results were followed up for more than 2 years (2.3 ± 1.3 years). The breakdown of decompression sections was 68 cases at 1 level, 7 cases at 2 levels and 3 cases at 3 levels. The most frequently involved level was L4–5 (56 cases decompressed), followed by L3–4 (25 cases), L2–3 (7 cases), and L5–S1 (3 cases) (Table 1). The average age was 72.8 ± 9.2 years old (from 53 to 92 years), 48 males and 30 females. Neurogenic intermittent claudication was 150 ± 118 m on average, ranging from 10 to 500 m. Mean symptom duration was 19.2 ± 15.5 months, ranging from 5 to 57 months. We evaluated the visual analogue scale (VAS), Japanese Orthopedic Association (JOA) score, Oswestry Disability Index (ODI), modified MacNab criteria, and complications. We surveyed in 1 month, 3 months, 6 months, 1 year, 2 years by the questionnaire method described by the patient himself. However, statistical processing was analyzed after 1 month and 2 years.¹²⁻¹⁵

The statistical result for comparing preoperative and postoperative results was performed with the paired 2-tailed Student

Table 1. Details of number of levels decompressed

Level	L2/3	L3/4	L4/5	L5/S
1 Level	3 Cases	15 Cases	47 Cases	3 Cases
2 Levels	6 Cases (L3/4/5)			
	1 Case (L2/L3/4)			
3 Levels	3 Cases (L2/3/4/5)			

Ninety-one levels of 78 patients were operated. Breakdown was 68 cases at 1 level, 7 cases at 2 levels, 3 cases at 3 levels. The most frequently decompressed levels were L4/5 (56 cases), L3/4 (25 cases), L2/3 (7 cases), and L5/S1 (3 cases).

Table 2. Clinical result

Evaluation item	Preoperative	After 1 month	p-value*	After 2 years	p-value*
VAS	7.1 ± 5.7	1.9 ± 2.3	<0.005	1.8 ± 2.1	<0.005
JOA score	9.9 ± 5.9	20.6 ± 8.9	<0.005	21.2 ± 5.5	<0.005
ODI	61.5 ± 22.2	22.8 ± 5.1	<0.005	21.6 ± 4.9	<0.005

Values are presented as mean \pm standard deviation.

The preoperative visual analogue score (VAS), the Japanese Orthopedic Association (JOA) score, and Oswestry Disability Index (ODI) in 78 cases significantly improved after 1 month ($p < 0.005$), and after 2 years ($p < 0.005$).

*Paired t-test.

t-test (analysis using IBM SPSS Statistics ver. 22.0 [IBM Co., Armonk, NY, USA]). The preoperative VAS 7.1 ± 5.7 in 78 cases significantly decreased to 1.9 ± 2.3 after 1 month ($p < 0.005$), and 1.8 ± 2.1 just after 2 years ($p < 0.005$). The JOA score increased significantly from 9.9 ± 5.9 preoperatively to 20.6 ± 8.9 after 1 month ($p < 0.005$) and it was 21.2 ± 5.5 just after 2 years ($p < 0.005$). ODI also significantly improved, from 61.5 ± 22.2 to 22.8 ± 5.1 after 1 month ($p < 0.005$) and it was 21.6 ± 4.9 at just after 2 years ($p < 0.005$). The operation time was 84 ± 23 min-

utes in 68 cases at 1 level. The mean hospital stay was 2.01 ± 0.4 days (Table 2).

The overall results in a modified MacNab criteria just after 2

Table 3. Outcome by MacNab criteria

MacNab grade	After 2 years, n (%)
Satisfactory	67 (85.9)
Excellent	31 (39.7)
Good	36 (46.2)
Unsatisfactory	11 (14.1)
Fair	7 (9.0)
Poor	4 (5.1)

A modified MacNab's result after 2 years were 67 patients (85.9%, *excellent* and *good*) with satisfaction and 11 patients (14.1%, *fair* and *poor*) with unsatisfaction.

years were as follows; 31 patients or 39.7% were *excellent*, 36 patients or 46.2% were *good*, 7 patients or 9.0% were *fair*, and 4 patients or 5.1% were *poor*. 67 patients (85.9%) were satisfied with the result of *excellent* and *good*. Eleven patients (14.1%) were unsatisfied with the results of *fair* and *poor* (Table 3). Unsatisfied results were as follows; 3 cases showed no changes in bilateral gastrocnemius manual muscle testing (MMT) 2 to 3,

Table 4. Unsatisfied group 14% (*fair* 7 cases & *poor* 4 cases)

Preoperative	Postoperative	Patients	MacNab criteria
Muscle weakness	No change	3 Cases	Fair 2, poor 1
Intermittent claudication	No change	4 Cases	Fair 3, poor 1
Dysesthesia	No change	3 Cases	Fair 2, poor 1
Paresis	Aggravated	1 Case	Poor 1

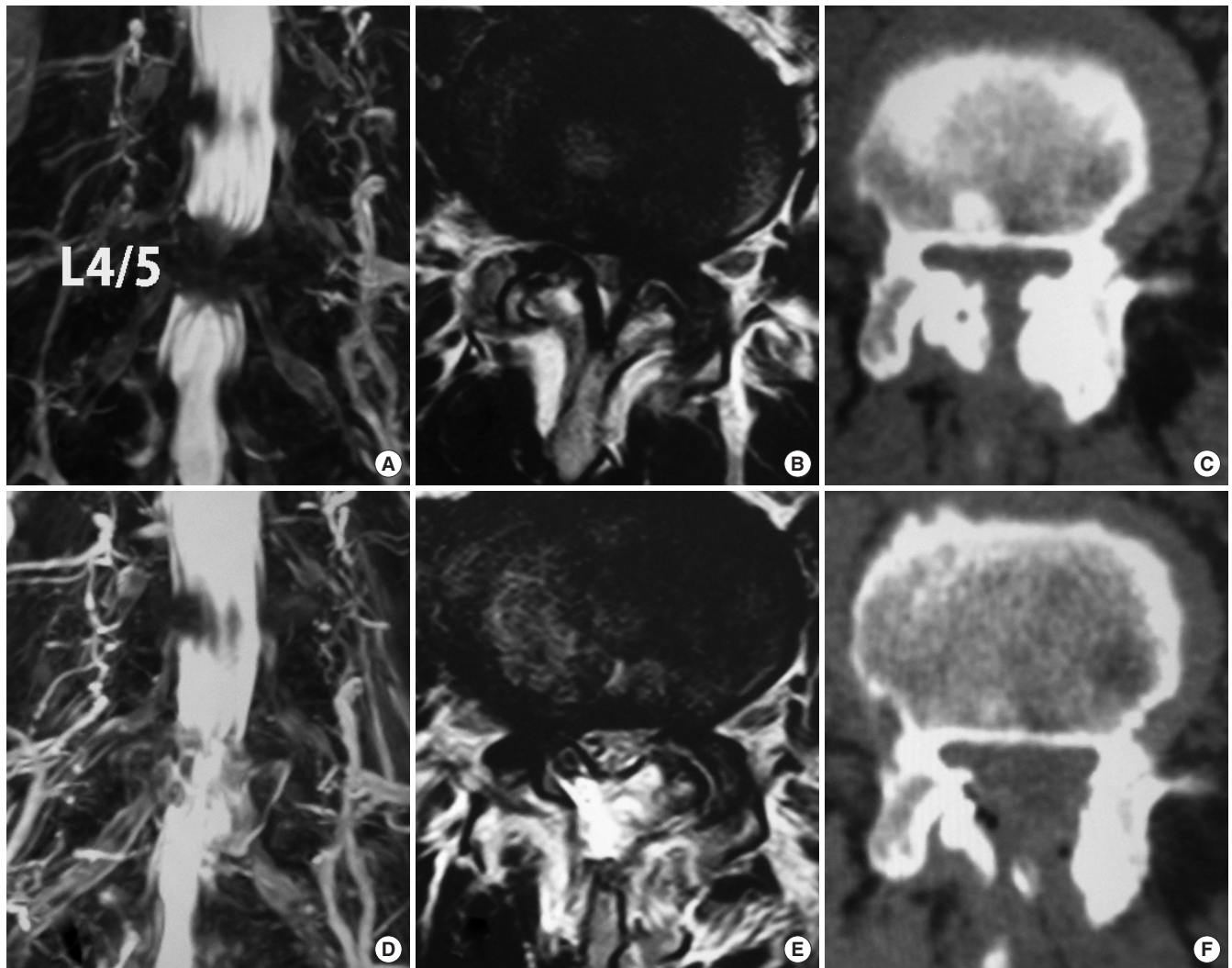


Fig. 8. Case 1. (A–C) Preoperative magnetic resonance imaging (MRI) and computed tomography (CT) showing the severe L4–5 spinal stenosis. (D–F) Postoperative MRI and CT showing well decompression of spinal stenosis.

and no improvements of walking were observed. Four cases within 20 m of intermittent claudication were unsatisfactory without improvement as expected. Three cases had no changes of severe dysesthesia and numbness on the lower limbs. One case was presumed to be due to contralateral excessive pressure on the contralateral L5 nerve root during the operation, and the tibialis anterior muscle MMT 4 worsened to 2 just postoperatively, but recovered to 4+ after 6 months. This patient was operated on unfortunately in the early stage of introduction of this method (Table 4).

Dural tear happened in 4 cases (5.1%), and patch repair techniques were performed using fibrin glue under endoscopy. Those techniques did not affect the results. There were no postoperative infection cases. One case of postoperative hematoma and 1 case of incomplete decompression were operated on in the same way after 5 days and 7 days respectively. No patients showed posterior opening spinal segment instability of more than 10° in dynamic radiographs. There was no example where the spondylolisthesis within grade 1 in Meyerding criteria was aggravated to more than grade 2.

1. Case presentation

1) Case 1

The patient was a 69-year-old male. Intermittent claudication progressed during 2 years and walking distance was to within 30 m just before surgery. During walking and standing, pain and numbness were radiated from both buttocks to the posterior or lateral side of both thighs. Preoperative VAS was 7.5, JOA score was 14, and ODI was 61. Two years later, the VAS was 2, the JOA score was 23, ODI was 24 and walking ability was above 1.5 km (Fig. 8).

2) Case 2

The patient was a 62-year-old male, a physical exercise teacher. Severe low back pain and left buttock pain without leg symptoms continued for 4 months due to LCCS of L2–3 level with a synovial cyst. Preoperative VAS was 8.0, JOA score was 9, and ODI was 74. One year later, the VAS was 0, and the JOA score was 28 (Fig. 9).

DISCUSSION

Minimally invasive spine decompression surgery has many

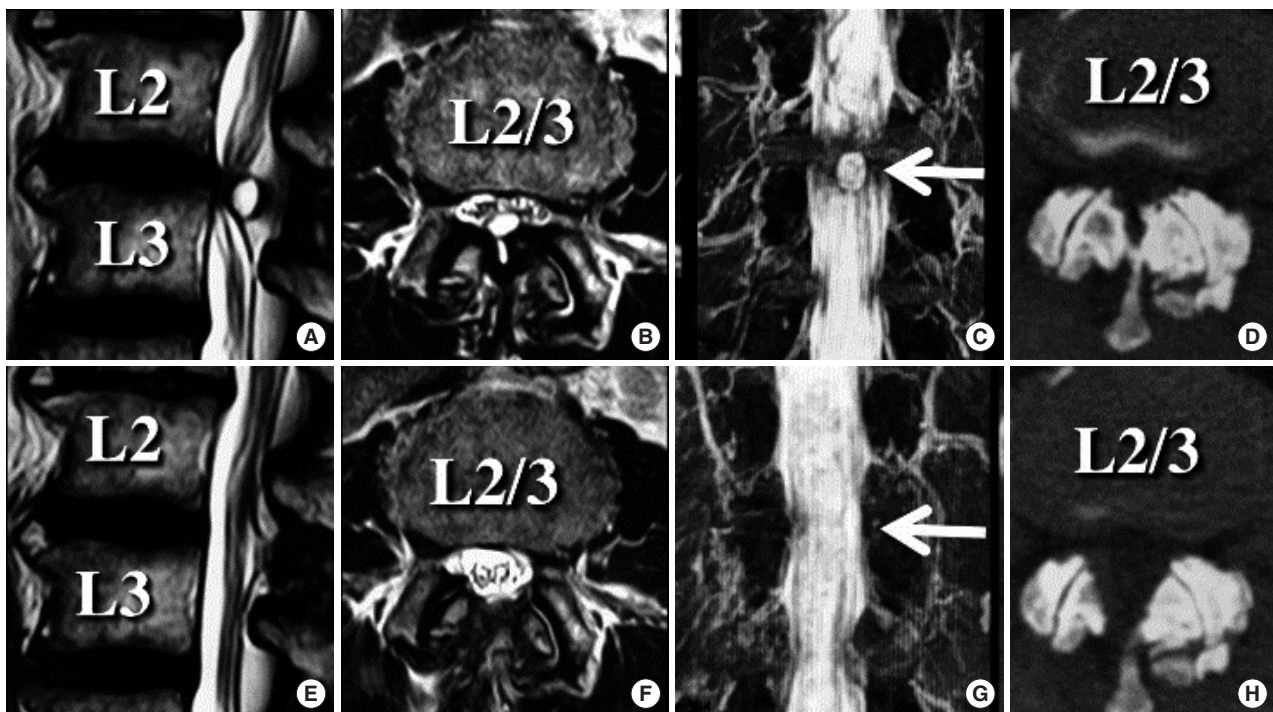


Fig. 9. Case 2. (A–D) Preoperative magnetic resonance imaging (MRI) and computed tomography (CT) showing a synovial cyst of L2–3 and lumbar central canal stenosis. (E–H) Postoperative MRI and CT showing well decompression of spinal stenosis. Arrow in panel C: preoperative pathologic area (cyst & stenotic dura); arrow in panel D: postoperative improved area (no cyst & dilated dura).

advantages such as requiring a small incision, shorter time for soft tissue debridement, less muscle injury, similar instruments as with open surgery, easy bone resection, short operation time, short term hospitalization, possibility to be made available also for obese patients, one small incision for multiple segment lesions, similar postoperative results to conventional methods, and fewer complications, etc.

The endoscopic decompression solved the problems above and could be fully applied to daily practice. Specifically, after resecting the lower part of the cephalad lamina, an oblique outer tube can directly dock on the interlaminar space, and soft tissue is easily removed and immediately approaches the shallow layer of the ligamentum flavum. First of all, cut the shallow layer as thin as possible with a punch forceps or a Kerrison punch. It is the key point to prevent unnecessary bleeding by leaving the deep layer intact to the end and preserving the capillary bed layer on the dura.

The entheses of the deep ligamentum flavum is removed with a Kerrison or diamond burr. If the surrounding attachment is separated and released, it becomes possible to cut out as a whole. However, in the presence of adhesion, some part of the deep layer of the ligamentum flavum, the epidural adipose layer, and the capillary layer may be left. Because with the endoscopic decompression method it is easy to incline the endoscope to the contralateral side by the unilateral approach method, the contralateral side of the intervertebral foramen and the lateral recess can be seen under the endoscope in detail. Therefore, the surgeon is recommended to stand on the opposite side against more hypertrophy of vertebral lamina or marked stenosis of the lateral recess on CT transverse image, so he can sufficiently perform contralateral decompression.

Our step-by-step sublaminar endoscopic decompression method is a unilateral approach for bilateral decompression. The posterior support elements, such as the muscle, interspinous ligament and spinous process are almost completely preserved. The fenestration part is smaller than that of MEL, microscope and quadrant method. This prevents invasion of the scar tissue from the back.

The endoscopic decompression outer tube is less muscle retraction and less lamina removing compared with the conventional 16-mm MEL outer tube or the CASPER retractor.

The inferior articular facet of the high-level lumbar lamina is very narrow. When the conventional 16-mm MEL outer tube is used, it is difficult to remove the ipsilateral lamina without excess resection of the inferior articular facet. On the other hand, endoscopic decompression outer tube is relatively narrow, and

the ipsilateral lamina can be easily preserved, especially on the upper lumbar level without excess resection. This approach and technique will minimize the damage to the facet joint and prevent the occurrence of new instability. Compared to the outer tube of MEL and CASPER of 8 cm in length, the length of the endoscopic decompression endoscope and its outer tube is 12 cm, so there is no problem in the case of the obese.

In cases of only thickening of the ligamentum flavum, epidural anesthesia is also possible, and it is possible by one incision for the laminar hypertrophy, joint hypertrophy and multiple spinal segments disorder (up to 3 segments) under general anesthesia. Because the ligamentum flavum is excised, continuous irrigation water flows out of the body through the endoscope. Since irrigation water mildly rises to the epidural space, the intracranial pressure elevation is not so high. However, in case of dural tear, high-pressure irrigation water easily flushes into the subarachnoid space, which directly causes compression of the conus medullaris and elevates intracranial pressure, which is dangerous. First of all, it is important to repair the dura to prevent water flow into the arachnoid space. A fibrinogen immersed Bicryl-mesh or Neovail, or a fibrin sealant patch (TachoSil, Baxter Healthcare Corp., Deerfield, IL, USA) is applied to the ruptured dura.¹⁶⁻¹⁸

The step-by-step sublaminar endoscopic decompression method is a practical minimally invasive treatment for spinal diseases requiring decompression such as LCCS, lumbar foraminal stenosis, lumbar lateral recess stenosis, cervical foraminal stenosis, and cervical radiculo-myelopathy at 1 or 3 segments in an aging society.^{19,20}

CONCLUSION

The step-by-step sublaminar endoscopic decompression can use similar decompression instruments to the MEL or microscopic laminectomy with a small incision of 9 mm. Decompression of the contralateral side is more fully possible and decompression on of the ipsilateral side is relatively easy. It can also preserve the paraspinal muscles and the posterior elements—including the laminae, pedicles, spinous processes, interspinous ligaments, and facet joints. This is a relatively easy and safe method as a practical decompression technique for spinal canal stenosis. It is expected that this method will be widely adopted especially for elderly people. However, to obtain more accurate results, more patients and longer follow-up times are required. This is a preliminary investigation, but it can be expected to be a hint for future results analysis.

CONFLICT OF INTEREST

The authors have nothing to disclose.

ACKNOWLEDGMENTS

I would like to thank Dr. Kangtaek Lim, Dr. Gun Choi, Dr. Hyeun Sung Kim of Korea and Dr. Dezawa of Japan who gave me a reference opinion on technical aspects of surgery. Especially I would like to express my sincere gratitude to Dr. Hyeun-Sung Kim for proofreading sentences and organizing beautiful original illustrations.

SUPPLEMENTARY MATERIAL

Supplementary video clip 1 can be found via <https://doi.org/10.14245/ns.1836320.160.v1>.

REFERENCES

1. Minamide A, Yoshida M, Yamada H, et al. Endoscope-assisted spinal decompression surgery for lumbar spinal stenosis. *J Neurosurg Spine* 2013;19:664-71.
2. Enyo Y, Yamada H, Kim JH, et al. Microendoscopic lateral decompression for lumbar foraminal stenosis: a biomechanical study. *J Spinal Disord Tech* 2014;27:257-62.
3. Khoo LT, Fessler RG. Microendoscopic decompressive laminotomy for the treatment of lumbar stenosis. *Neurosurgery* 2002;51(5 Suppl):S146-54.
4. Nomura K, Yoshida M. Microendoscopic decompression surgery for lumbar spinal canal stenosis via the paramedian approach: preliminary results. *Global Spine J* 2012;2:87-94.
5. Pao JL, Chen WC, Chen PQ. Clinical outcomes of microendoscopic decompressive laminotomy for degenerative lumbar spinal stenosis. *Eur Spine J* 2009;18:672-8.
6. Nakamura S, Shibayama M. Rectangular tubular retractor for microendoscopic lumbar decompression. *J Neurol Surg A Cent Eur Neurosurg* 2017;78:191-7.
7. Ito F. Percutaneous endoscopic lumbar discectomy (PELD)—transforaminal and interlaminar approaches—essential practice of neurosurgery. Nagoya (Japan): Access Publishing Co., Ltd.; 2010:939-46.
8. Ito F, Miura Y, Nakamura S, et al. Percutaneous endoscopic lumbar discectomy (PELD): transforaminal approach and indications. *Asian J Neurosurg* 2008;11:41-6.
9. Komp M, Hahn P, Oezdemir S, et al. Bilateral spinal decompression of lumbar central stenosis with the full-endoscopic interlaminar versus microsurgical laminotomy technique: a prospective, randomized, controlled study. *Pain Physician* 2015;18:61-70.
10. Lee CW, Yoon KJ, Jun JH. percutaneous endoscopic laminotomy with flavectomy by uniportal, unilateral approach for the lumbar canal or lateral recess stenosis. *World Neurosurg* 2018;113:e129-37.
11. Kim HS, Paudel B, Jang JS, et al. Percutaneous full endoscopic bilateral lumbar decompression of spinal stenosis through uniportal-contralateral approach: techniques and preliminary results. *World Neurosurg* 2017;103:201-9.
12. Ahn Y. Percutaneous endoscopic decompression for lumbar spinal stenosis. *Expert Rev Med Devices* 2014;11:605-16.
13. Izumida S, Inoue S. Assessment of treatment for low back pain. *J Jpn Orthop Assoc* 1986;60:391-4.
14. Fairbank JC, Pynsent PB. The Oswestry Disability Index. *Spine (Phila Pa 1976)* 2000;25:2940-52.
15. Matsumoto M, Hasegawa T, Ito M, et al. Incidence of complications associated with spinal endoscopic surgery: nationwide survey in 2007 by the Committee on Spinal Endoscopic Surgical Skill Qualification of Japanese Orthopaedic Association. *J Orthop Sci* 2010;15:92-6.
16. Joh JY, Choi G, Kong BJ, et al. Comparative study of neck pain in relation to increase of cervical epidural pressure during percutaneous endoscopic lumbar discectomy. *Spine (Phila Pa 1976)* 2009;34:2033-8.
17. Choi G, Kang HY, Modi HN, et al. Risk of developing seizure after percutaneous endoscopic lumbar discectomy. *J Spinal Disord Tech* 2011;24:83-92.
18. Shibayama M, Mizutani J, Takahashi I, et al. Patch technique for repair of a dural tear in microendoscopic spinal surgery. *J Bone Joint Surg Br* 2008;90:1066-7.
19. Kim JH, Kim HS, Kapoor A, et al. Feasibility of full endoscopic spine surgery in patients over the age of 70 years with degenerative lumbar spine disease. *Neurospine* 2018;15:131-7.
20. Kim JH, Kwon YJ. Long-term clinical and radiological outcomes after central decompressive laminoplasty for lumbar spinal stenosis. *Korean J Spine* 2017;14:71-6.